

Case of the month

October 2011

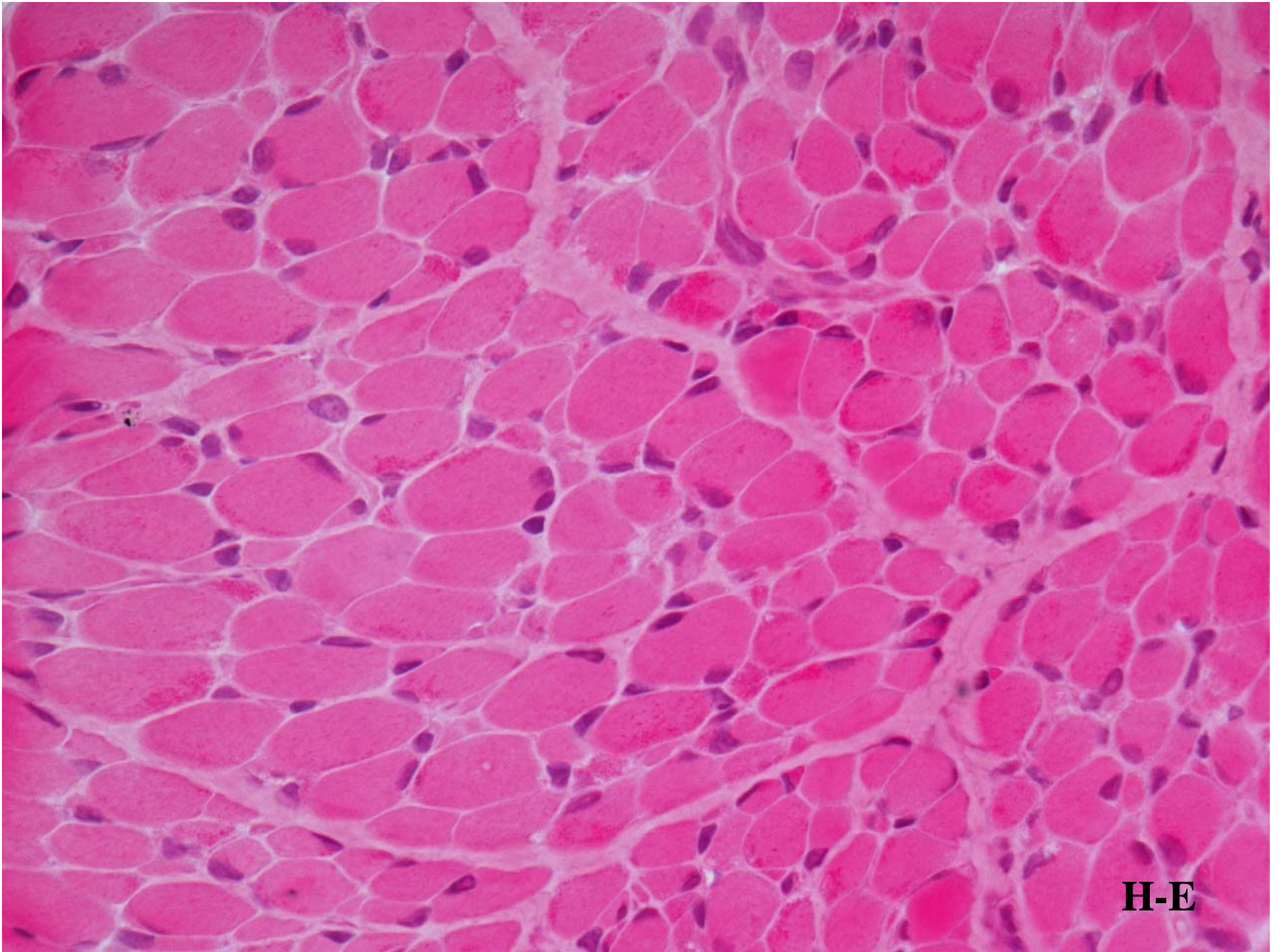
Inger Nennesmo

Karolinska University Hospital

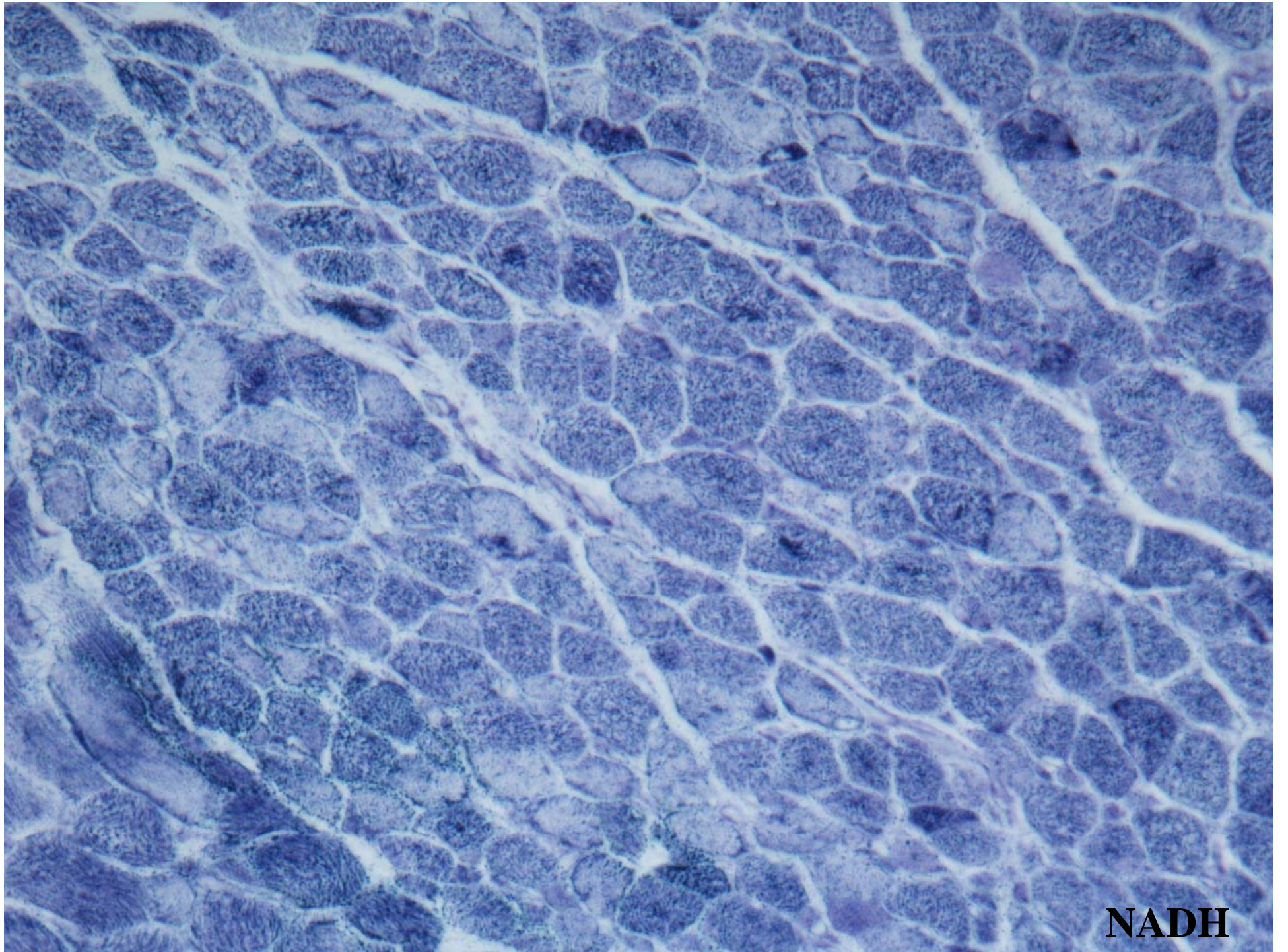
Stockholm Sweden

Case history

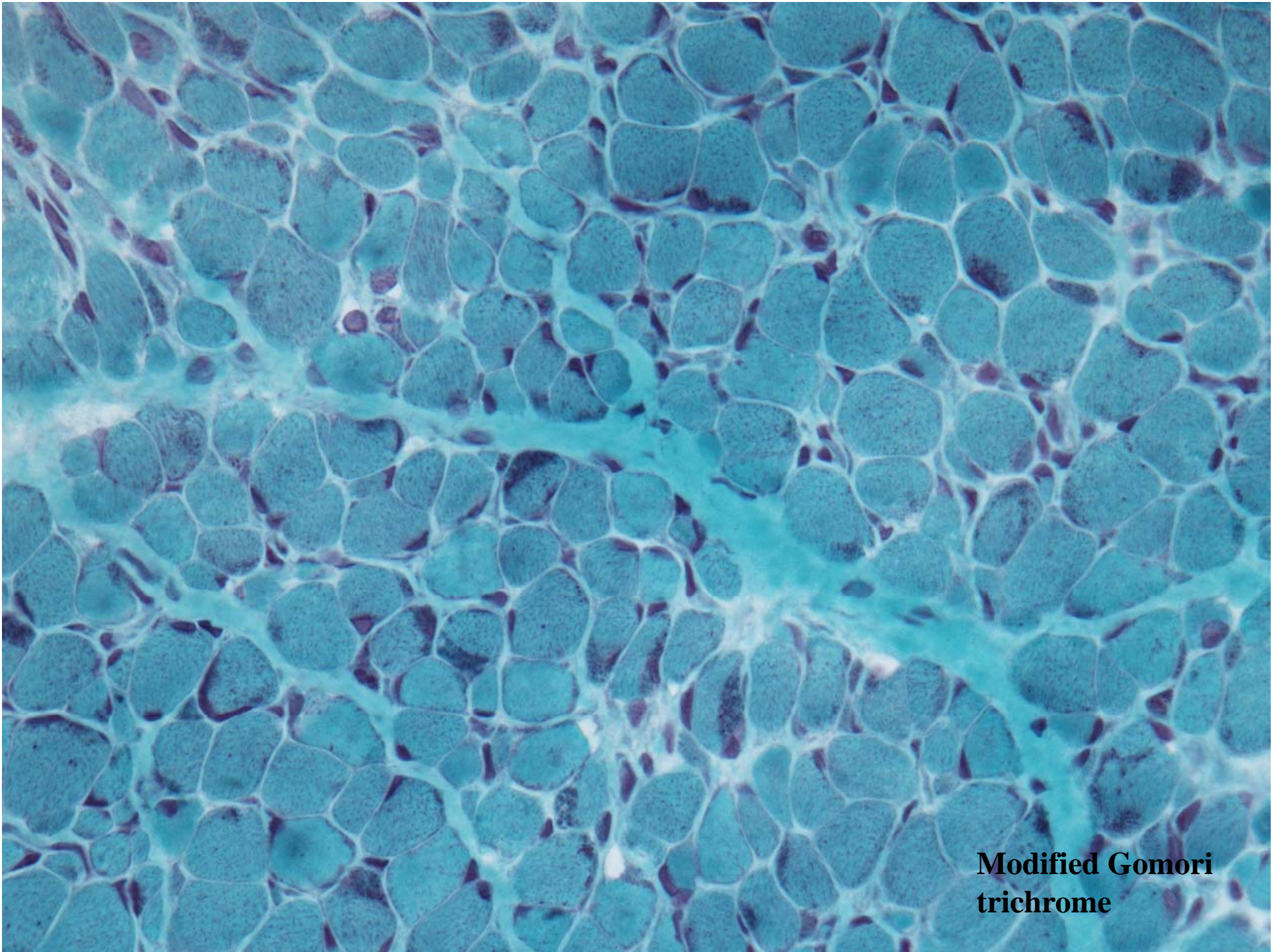
Newborn boy with severe muscle weakness. Respiratory problems. Sucking and swallowing difficulties. EMG/ENeG normal. MRT of brain normal.



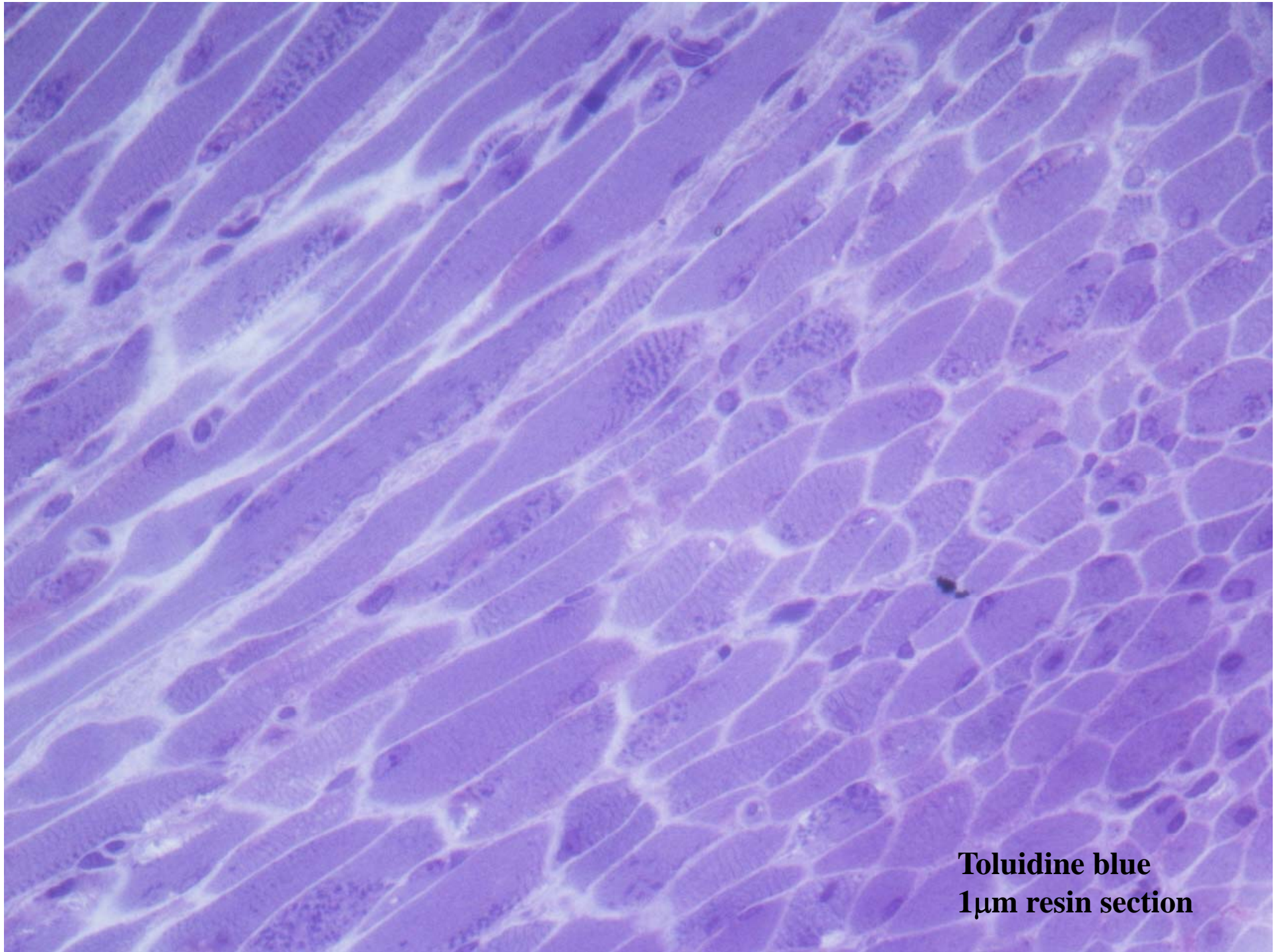
H-E



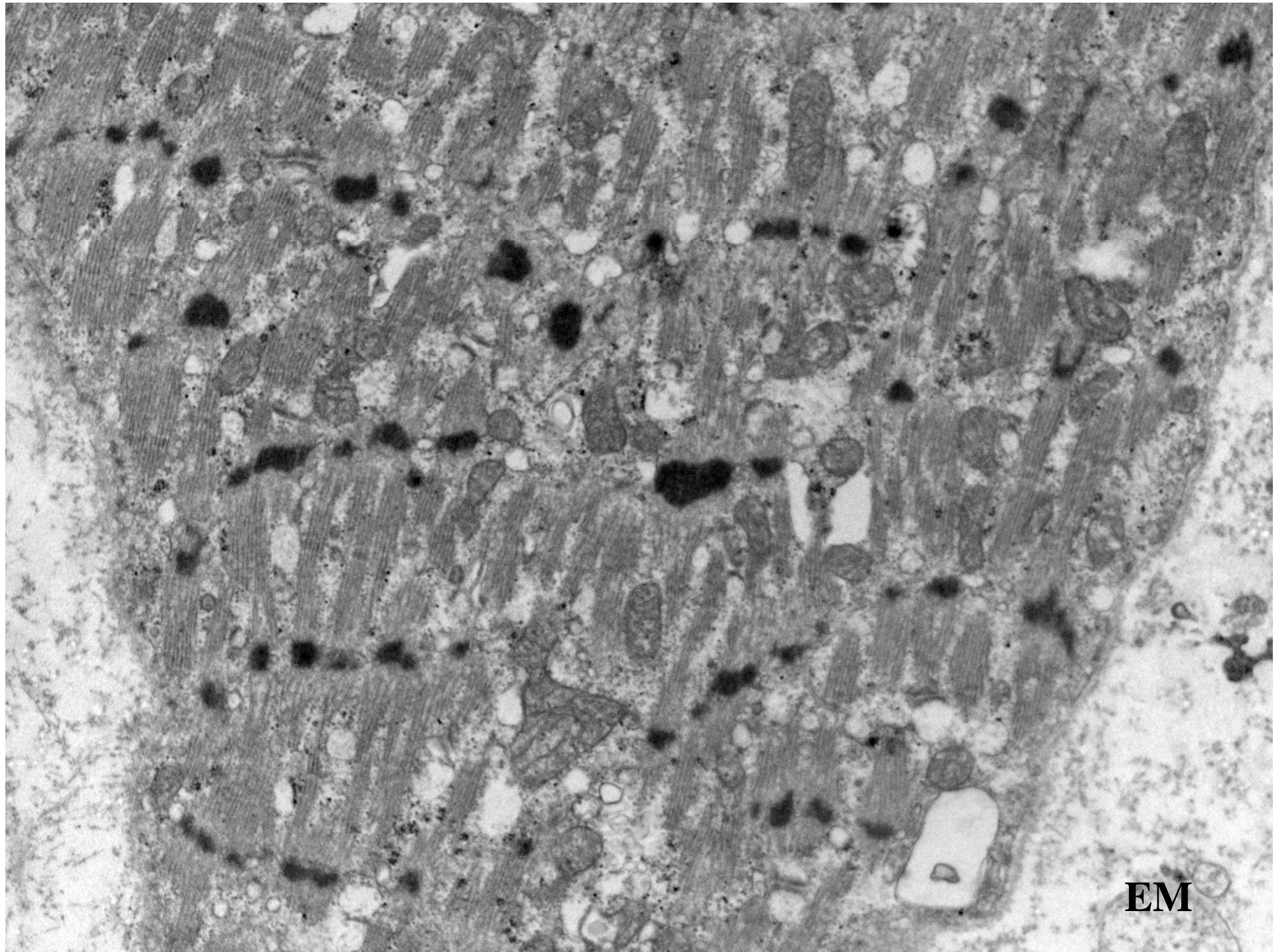
NADH



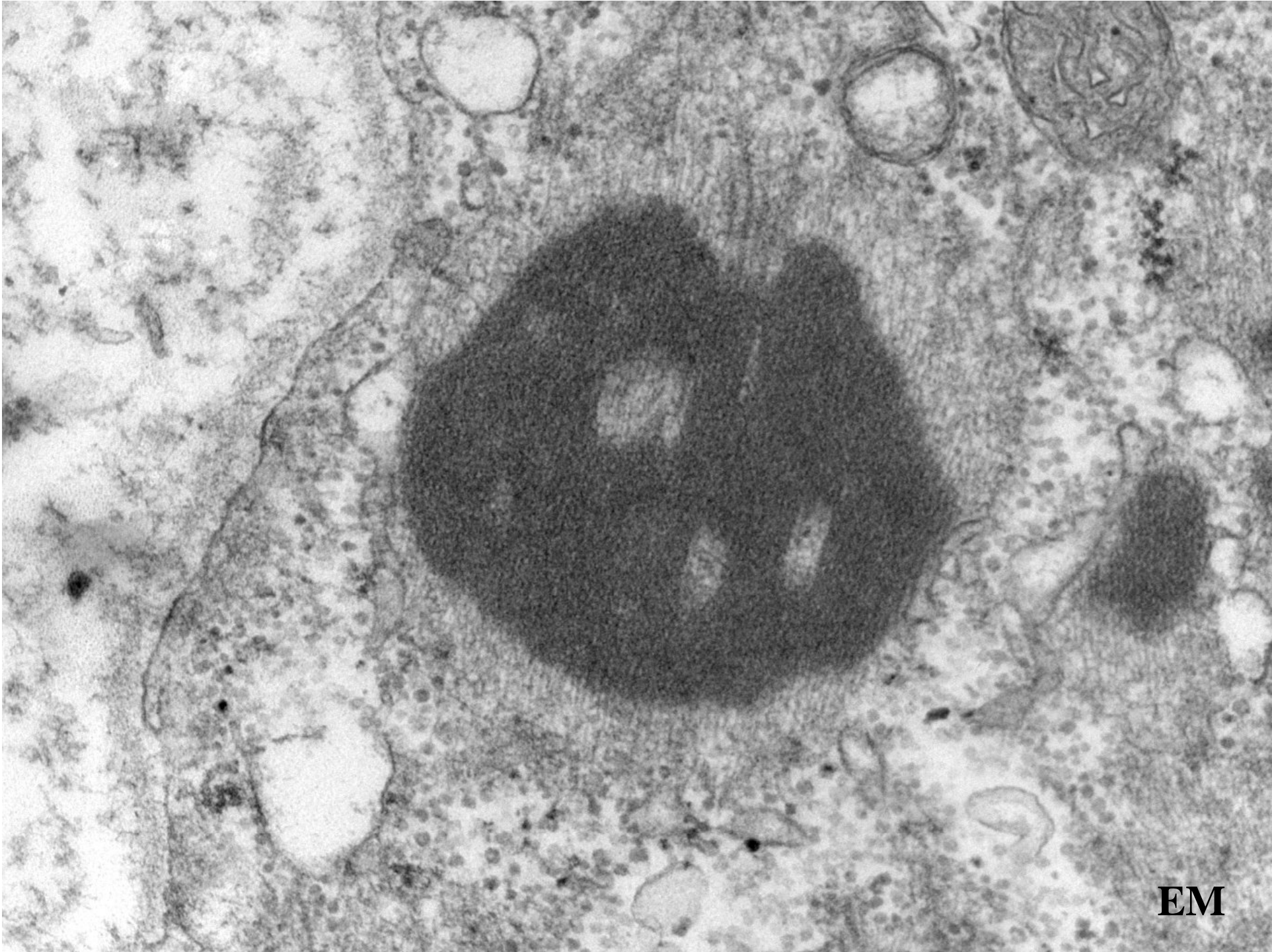
**Modified Gomori
trichrome**



Toluidine blue
1 μ m resin section



EM



EM