

Case of the month

December 2011

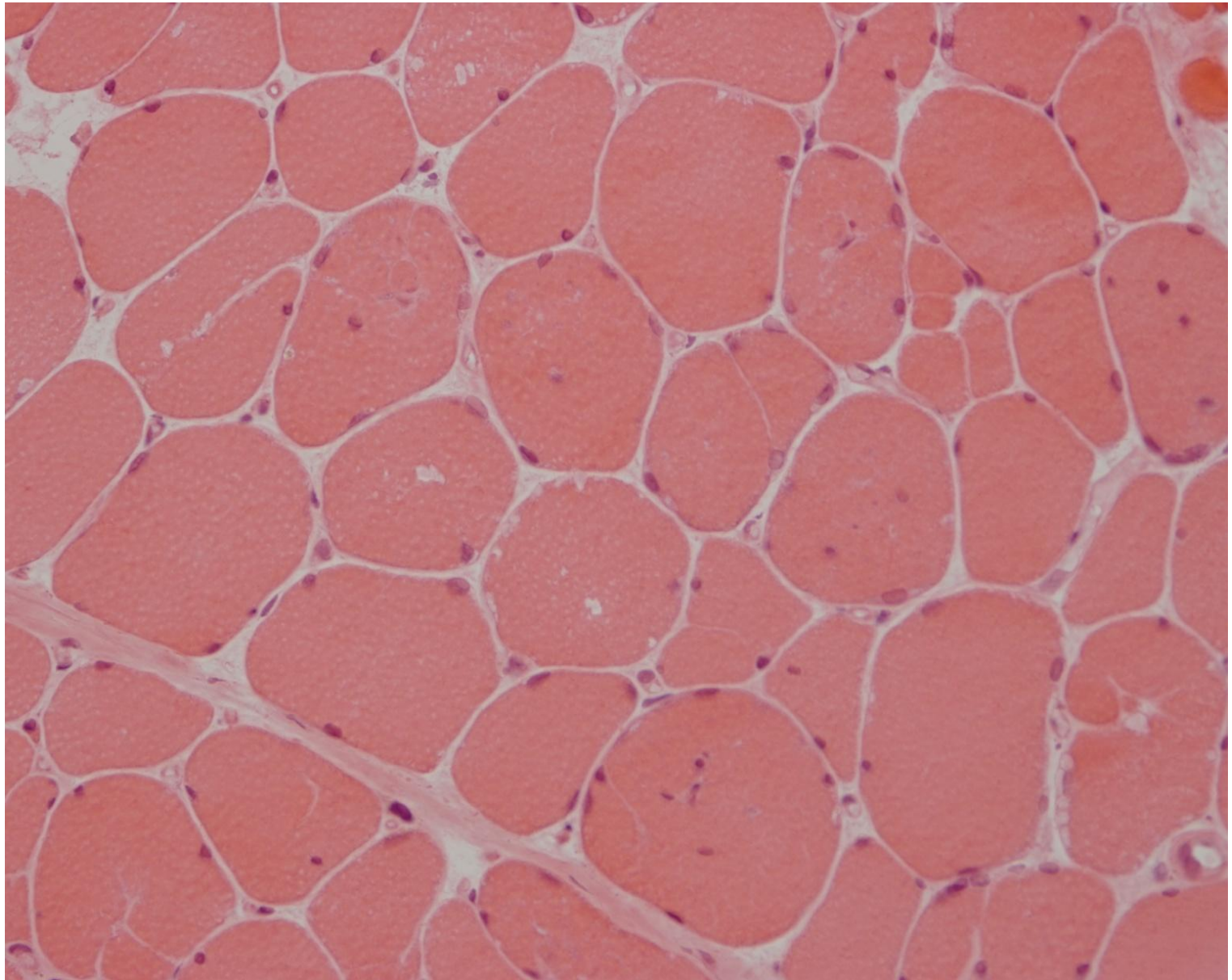
Inger Nennesmo

Karolinska University Hospital

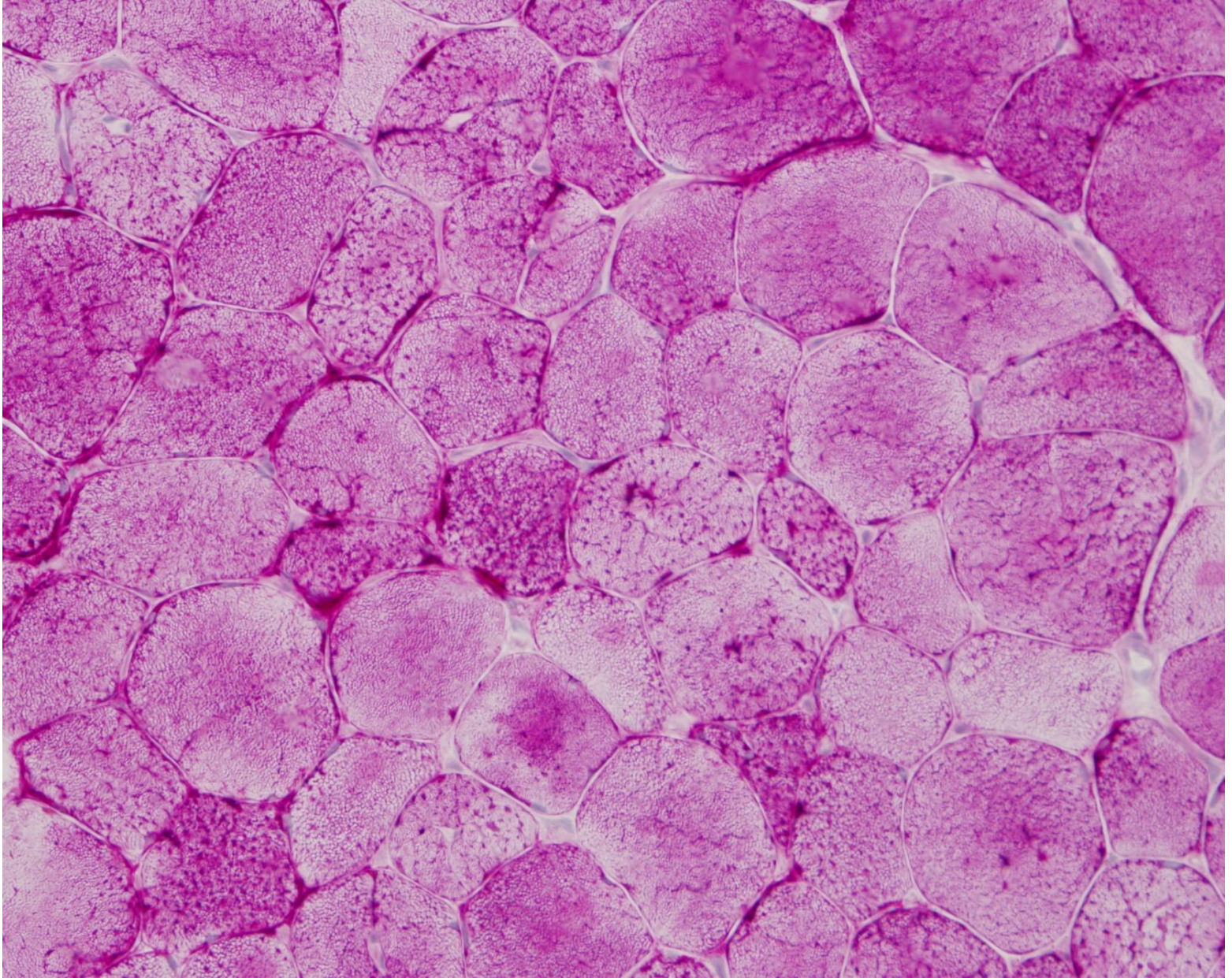
Stockholm Sweden

Case history

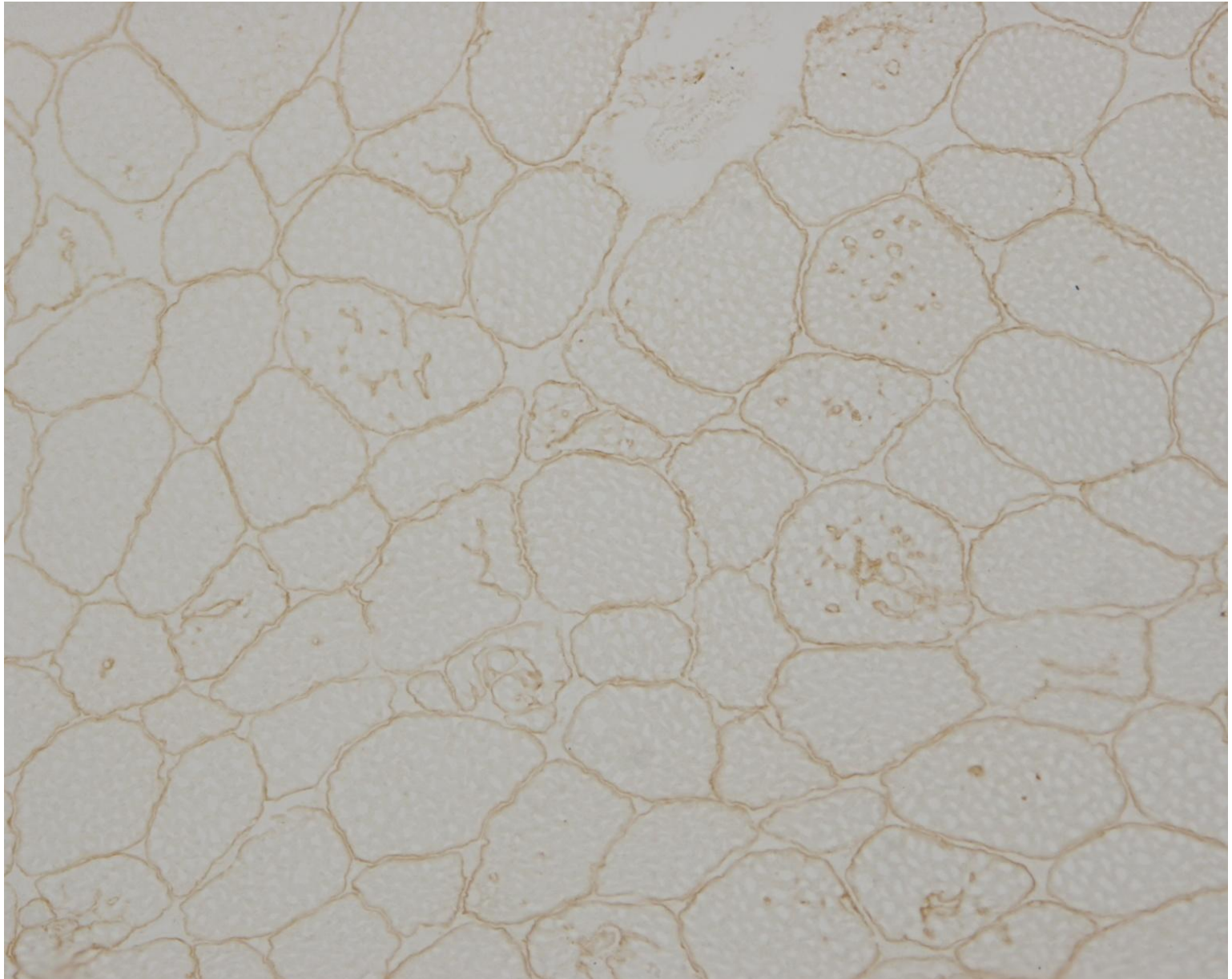
Twenty years old male with muscle weakness since childhood with severe deterioration the last couple of years. For some months also cardiac problems. Dies of cardiac failure. Mother had cardiomyopathy.



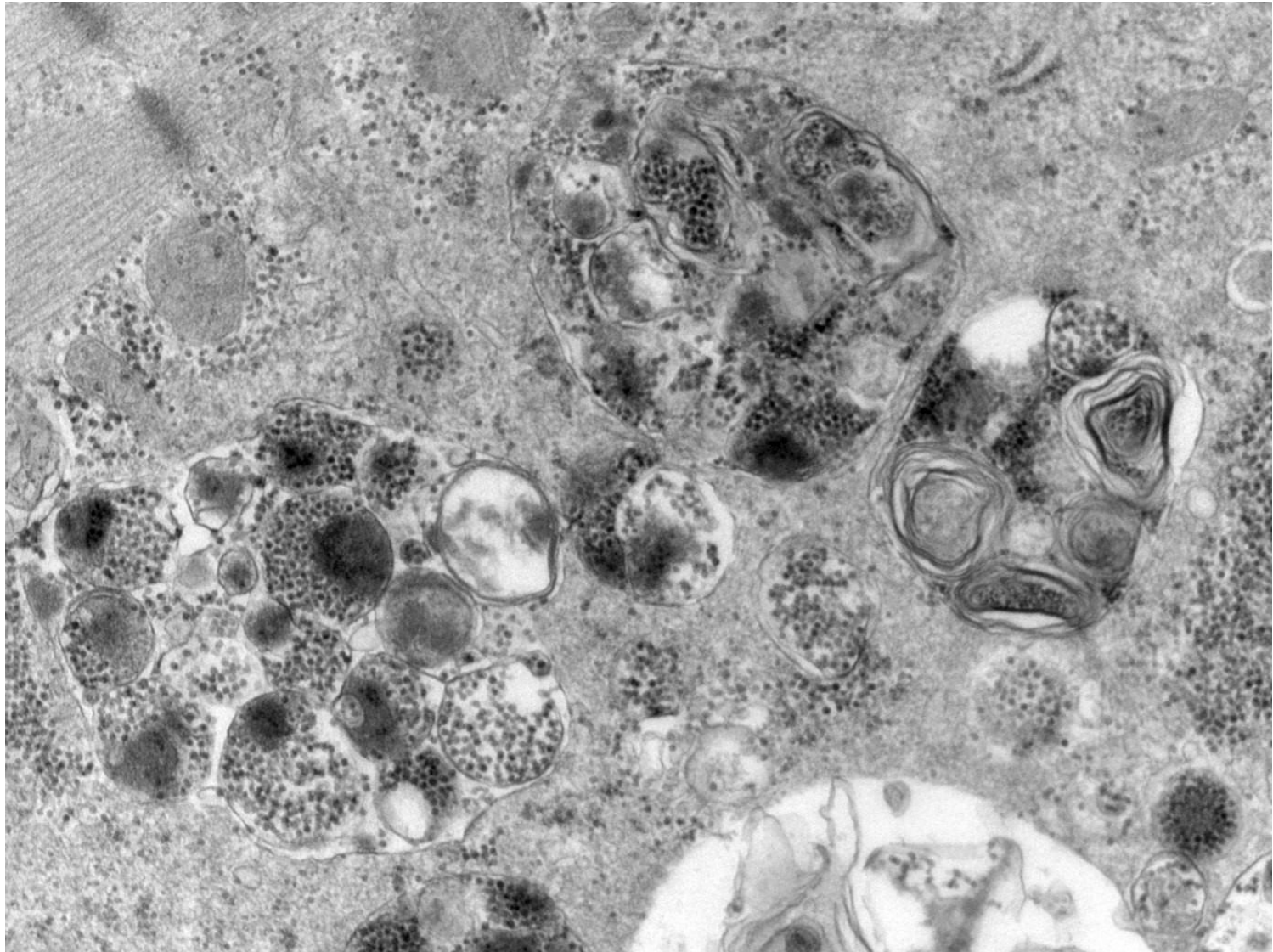
H-E



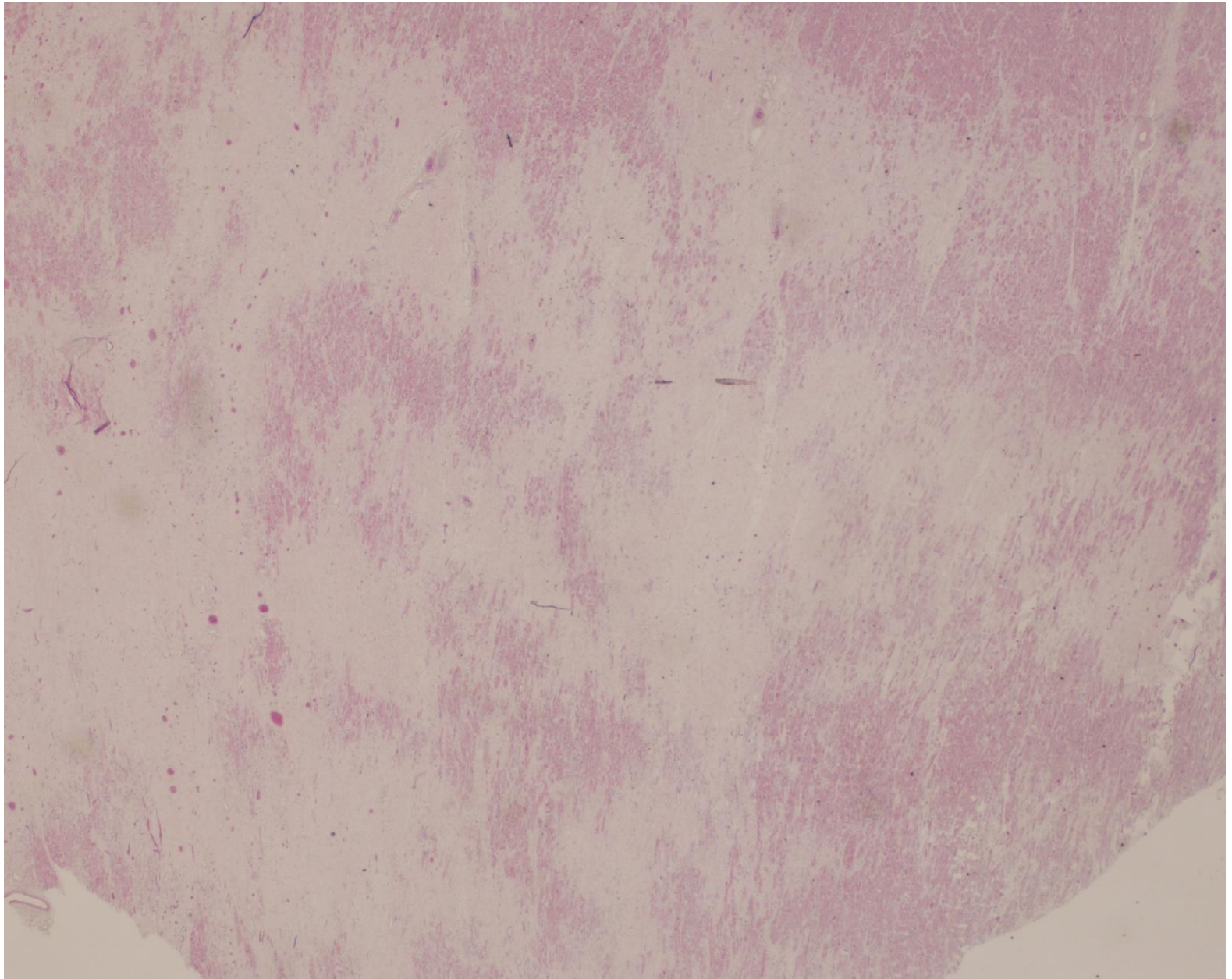
PAS



Dystrophin



Electron microscopy



Myocardium